

Case Report 1

Team Treatment Planning for the Replacement of Esthetic Zone Teeth with Dental Implants

Robert A. Levine, DDS; and Gary Nack, DDS

ABSTRACT

Implant therapy requires comprehensive preoperative planning and precise surgical execution based on a restorative-driven approach. Implant surgical demands in the esthetic zone require that the surgeon treating has extensive surgical experience in a variety of areas. Using a “team” approach to treat such cases allows the patient to receive care similar to the “medical model,” in which each member of the clinical team specializes in his or her respective area. This interdisciplinary approach to implant therapy is demonstrated in the case presented, which describes the restoration of an elderly patient’s failing maxillary dentition.

The planning of implant therapy in the anterior maxilla is an advanced or complex procedure based on the SAC Classification of cases.¹ Comprehensive preoperative planning and precise surgical execution based on a restorative-driven approach is needed.^{2,3} Esthetic risk factors must be addressed in each case prior to treatment to avoid any posttreatment misunderstandings the patient may have. The goal of risk assessment is to identify those patients for whom implant therapy carries a high risk of a negative outcome.⁴⁻⁶

Implant surgical demands in the esthetic zone require that the surgeon treating has extensive surgical experience in the following areas:

- flap management.
- minimally traumatic extraction techniques with buccal plate preservation as an important surgical goal.⁷
- knowledge of all periodontal plastic surgical procedures, from connective tissue (CT) grafting to gummy smile/excessive gingival display correction.⁸
- knowledge of cone-beam computed tomography (CBCT) scan usage and hard-tissue site development techniques such as guided bone regeneration (GBR).
- 3-dimensional (3-D) implant placement and surgical guide template fabrication.²⁻⁵
- knowledge of occlusion and prosthetic treatment plans.
- knowledge of periodontal maintenance and treatment of implant mucositis and peri-implantitis.⁸⁻¹⁰

Treating patients with a “team” approach is important for achieving the best long-term result. This allows the patient to receive care similar to the “medical model” in that each member of the clinical team is a specialist in his or her respective areas.¹¹ This interdisciplinary, comprehensive team approach has succeeded for decades in medicine as well as in dentistry and, in the end, benefits the patient.

INITIAL PRESENTATION

An 82-year-old healthy non-smoking man presented for restorative consultation regarding his failing maxillary dentition. His chief

complaint was lack of comfort during function and an unwillingness to smile due to broken teeth and poor esthetics. The patient reported poor compliance to preventive dental care and had not seen a dentist in many years. Following this initial discussion and preliminary examination of his hard and soft tissues, referral was made to the periodontist to evaluate surgical options for tooth replacement. After further discussions the periodontist performed a clinical examination, which included a definitive periodontal charting, mobility analysis, occlusal exam, and temporomandibular joint (TMJ) evaluation. The diagnosis found generalized early periodontitis with areas of severe nonrestorable recurrent caries (teeth Nos. 7, 9, and 10), periapical disease (tooth No. 10), and missing teeth (teeth Nos. 12, 14, and 29 through 31) (Figure 1 through Figure 4). Generalized moderate plaque and calculus deposits were noted, along with posterior interproximal food impaction and generalized bleeding upon probing. No parafunctional habits were noted.

Based on the patient’s esthetic risk factors at presentation, a low esthetic risk was assessed and reviewed with the patient (Figure 5). In discussions with the patient, and based on his low esthetic risk profile, the surgeon was more able to treat him with an immediate approach compared to other patients who may present with numerous medium and/or high risk factors. This would enable a more conservative surgical approach, reducing the chances of esthetic complications.

TEAM TREATMENT PLANNING

As part of the authors’ comprehensive team treatment planning protocol, a separate consultation visit was scheduled so that the restorative dentist could take alginate impressions for mounted study models to further facilitate the surgical and restorative

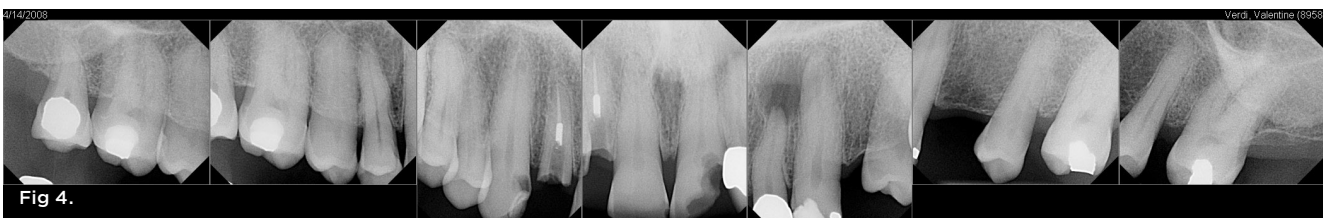
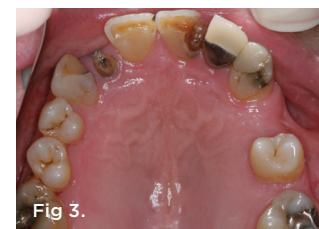
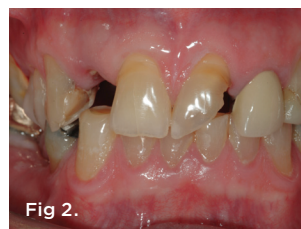
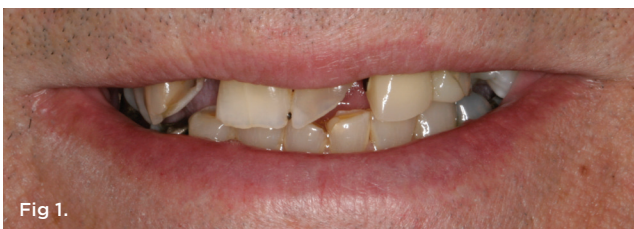Fig 1. Low lip line smile at presentation. **Fig 2.** Full buccal view at presentation. **Fig 3.** Occlusal view of maxilla at presentation. **Fig 4.** Maxillary periapical radiographs at presentation.

Case Report 1

IMPLANT ESTHETIC RISK PROFILE

Esthetic risk factors	Low	Medium	High
Medical status	Healthy patient and intact immune system		Reduced immune system
Smoking habit	Non-smoker	Light smoker < 10 Cig/D	Heavy smoker > 10 Cig/D
Patients esthetic expectations	Low	Medium	High
Lip line	Low	Medium	High
Gingival biotype	Low scalloped	Medium scalloped	High scalloped
Shape of tooth crowns	Rectangular	Slightly triangular	Triangular
Infection at implant site	None	Chronic	Acute
Bone level at adjacent teeth	≤ 5mm to contact point	5.5 to 6.5mm to contact point	7mm to contact point
Restoration status of neighboring teeth	Virgin		Restored
Width of edentulous span	1 tooth ≥ 7mm	1 tooth ≤ 7mm	2 teeth or more
Soft tissue anatomy	Intact soft tissue		Soft tissue defects
Bone anatomy of alveolar crest	No bone deficiency	Horizontal bone deficiency	Vertical bone deficiency

Fig 5. ✱ Low Esthetic Risk

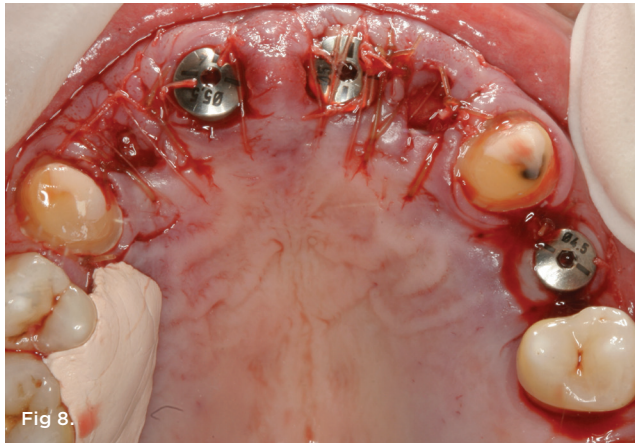
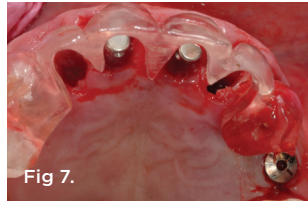
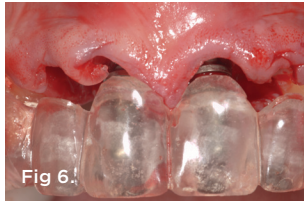


Fig 5. Implant esthetic risk profile for patient. **Fig 6.** Anatomically correct surgical guide with 2.8-mm direction indicators for sites Nos. 8 and 9. Ideal final placement will be 3.5 mm from the mid-buccal of the template to allow for adequate prosthetic emergence profile. **Fig 7.** 3.5-mm direction indicators are in place. Osteotomy site preparation is along the palatal walls of Nos. 8 and 9, leaving a buccal horizontal defect dimension of 2 mm to 3 mm requiring GBR. **Fig 8.** Final suturing with 4-0 chromic gut, 6-0 plain gut, and 6-0 Vicryl. The CT grafts have been placed over Bio-Oss mixed with calcium sulphate and covered with a Bio-Gide membrane for GBR. The CT grafts/socket seals help in membrane protection and soft-tissue augmentation. A small CT graft has also been placed buccal to the No. 9 implant and sutured to the undersurface of the flap to aid in improved buccal soft-tissue contours. Healing abutments at Nos. 8 and 9 are 5.5-mm x 4-mm height; healing abutment at site No. 12 is 4.5-mm x 4-mm.

treatment planning. The patient desired to phase his treatment plan with initial treatment of the maxillary arch followed by completion of the mandibular arch at a future date. The following options were discussed with the patient:

- *Option 1:* Removal of teeth Nos. 7 through 10 with placement of implants immediately (if possible) in sites Nos. 8, 9, and 12, with hard-tissue augmentation in sites Nos. 7 and 10 for ovate pontic development. The final proposed implant restorations in the maxilla were Nos. 7 through 10 and 12 with single porcelain crowns on Nos. 6 and 11.
- *Option 2:* Removal of teeth Nos. 7, 9, and 10 with fixed bridge-work on Nos. 6 through 13.

Further discussion involved the provisional options for the patient: 1) fixed provisional for Nos. 6 through 12; 2) resin-based removable appliance; or 3) no provisional.

The first option was chosen. Since the patient preferred not to have a removable transitional appliance during the healing phase, it was decided to place single temporary crowns on abutments Nos. 6 and 11 prior to surgery, with a coordinated patient return visit to the restorative dentist immediately postsurgery to have a laboratory-fabricated fixed provisional modified and inserted.

INITIAL RESTORATIVE PHASE

Alginate impressions were taken and stone casts made for the fabrication of a surgical guide template as well as for a BioTemps® metal-reinforced provisional (Glidewell Laboratories, www.glidewell dental.com) for teeth Nos. 6 through 12.

SURGICAL PHASE

The patient was premedicated with Amoxicillin 500 mg (2 g pre-surgery followed by 500 mg qid for 7 days), an oral antibacterial rinse (CHG 0.12%), and an NSAID (naproxen sodium 550 mg bid for 5 days), all starting 1 hour prior to surgery. Local infiltration of the soft tissues in the maxilla was completed at sites Nos. 4 through 13 with lidocaine with 1:100,000 epinephrine followed by 1:50,000 for surgical hemostasis. Full-thickness flaps were raised from No. 5 to the distal aspect of No. 8 and from the distal aspect of No. 9 to the mesial aspect of No. 13. The interproximal papilla between Nos. 8 and 9 was intentionally not raised to avoid postsurgical soft- and hard-tissue loss in this area. Surgical extractions were completed with Piezosurgery® surgical inserts EX1 and EX2 (Piezosurgery, www.piezosurgery.us) followed by the careful use of root tip forceps to remove Nos. 7 through 10. Piezosurgery was further used (insert OP5, Piezosurgery) with small surgical spoons to thoroughly clean out and debride the sockets. Maintenance of the buccal plates was accomplished using this minimally traumatic approach. Sites Nos. 8 and 9 were deemed

presurgically to be the best two sites for implant placement. This would result in cantilever restorations for the replacement of both lateral incisors.¹²

In anticipation of soft-tissue augmentation for sites Nos. 7 and 10, subepithelial CT grafts were taken from the palate bilaterally to aid in providing a “socket seal” and membrane protection over both sites after bone grafting and membrane placement.^{13,14} The anatomically correct surgical guide was positioned and used for 3-D placement using the palatal walls of sites Nos. 8, 9, and 12^{2,4} (Figure 6 and Figure 7). The implants were placed 3.5 mm from the apical extent of the mid-buccal aspect of the template. This required bone scalloping via osteoplasty for site No. 12. The implants placed were Astra Tech 4.5 mm x 13 mm (Astra Tech, www.astratech.com) tapered for Nos. 8 and 9, and a 4.0S x 11 mm for No. 12. The anticipated restorative platform switch has shown to provide bone maintenance with minimal crestal bone resorption compared to a non-platform-switch, same-size abutment and implant body connection. The use of platform switching can have benefits in esthetically sensitive areas with a thin biotype and triangular shaped teeth.¹⁵⁻¹⁷ Placed at Nos. 8 and 9 were 5.5-mm healing abutments; a 4.5-mm healing abutment was placed for No. 12. Socket preservation was completed for sites Nos. 7 and 10 with a slowly resorbing anorganic bone material (Bio-Oss®, Geistlich Pharma AG, www.geistlich.com) mixed with calcium sulphate and covered with a collagen membrane (Bio-Gide®, Geistlich Pharma AG). The previously harvested CT grafts were positioned over the membranes and for site No. 9 tucked under the buccal flap to plump out the soft tissues for an improved postoperative tissue profile. The flaps were closed with 6-0 Vicryl and 4-0 plain gut (Figure 8). Postoperative instructions were reviewed with the patient, who was then told to proceed directly to the restorative dentist’s office for the coordinated visit to modify and insert the laboratory-fabricated provisional. The patient left the periodontist’s office without a provisional in place.

COORDINATED RESTORATIVE VISIT

The patient was immediately seen (the same day as the surgery) by the restorative dentist at his office to reline and cement the fixed metal-reinforced laboratory-fabricated provisional restoration. Prior to cementation, the provisional was relieved in areas around Nos. 8, 9, and 12 to accommodate room for the healing abutments. In addition, the gingival areas of Nos. 7 and 10 were contoured with Jet acrylic (Lang Dental Manufacturing, www.langdentalmanufacturing.com) to create ovate pontics (Figure 9).

The provisional was cemented with TempBond® NE™ (Kerr Corporation, www.kerrdental.com), followed by Durelon™ (3M ESPE, www.3MESPE.com) at a subsequent visit for better retention after the provisional had come loose.

POSTOPERATIVE FOLLOW-UP

The patient was seen for follow-up and plaque control review at 2 weeks, 4 weeks, 6 weeks, and 12 weeks postsurgery. At the 12-week postoperative visit the provisional was removed and the soft tissues were evaluated. A reverse-torque test of all three implants was completed at 25 Ncm (confirming bone healing), periapical (PA) digital x-rays were taken, and the healing abutment for the No. 12 implant was replaced by one measuring 5.5 mm x 2 mm to stretch the tissues to help create the space needed for final emergence profile (Figure 10).

FINAL PROSTHETIC PHASE

At the 3-month postoperative visit a coordinated appointment was again scheduled to evaluate for initiation of the final restorative phase. At this visit further refinement of the ovate pontics was completed with electro-surgery under local anesthesia for site No. 10. Jet acrylic was added to the provisional to provide anticipated contour. Two weeks later, the provisional was once again removed. The ovate pontic sites were re-evaluated and appeared adequately

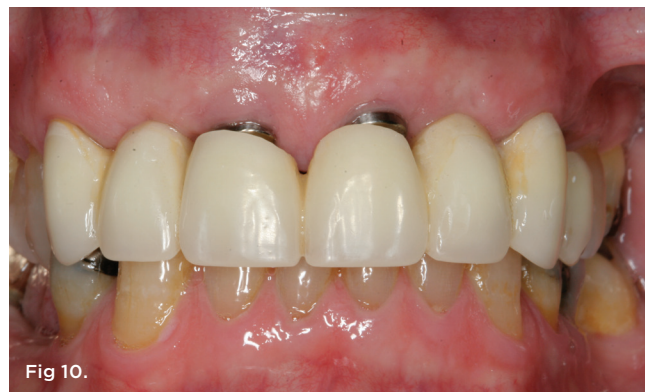
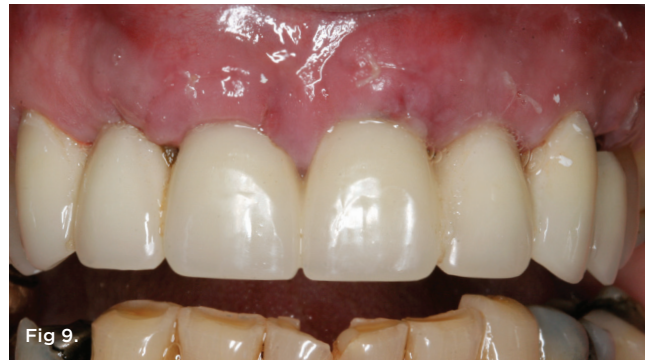
Fig 9. Day of surgery and insertion of provisional restoration (Nos. 6 through 12) by the restorative dentist immediately postsurgery.
Fig 10. 3-months postsurgery. Soft tissues have healed well from previous hard- and soft-tissue augmentation for ridge preservation, with maintenance of pontic sites Nos. 7 and 10.

Case Report 1

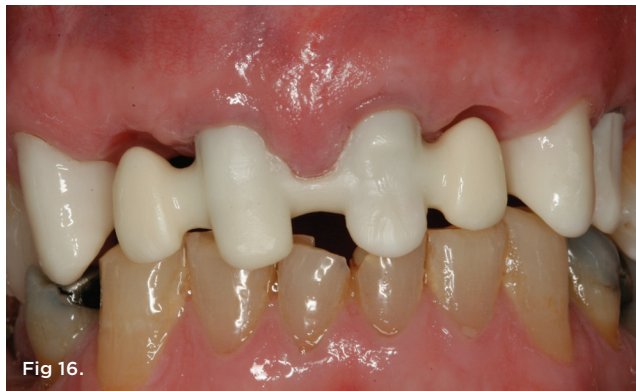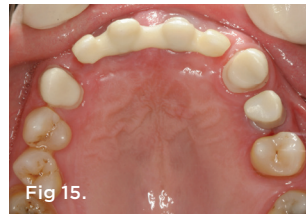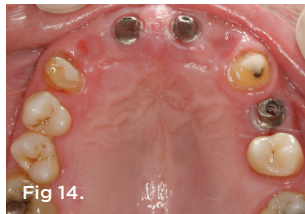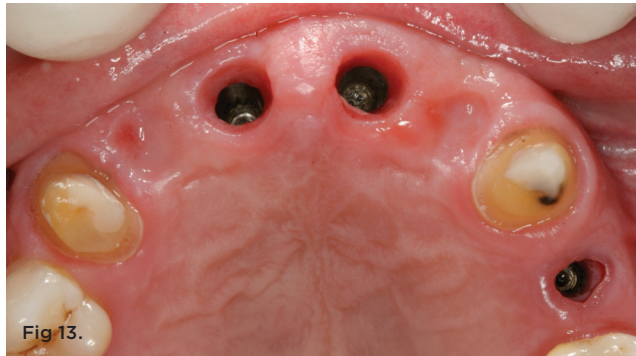
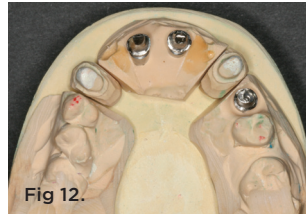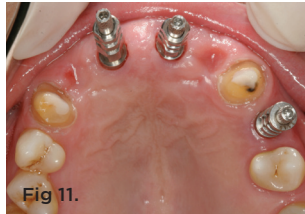


Fig 11. 3.5-month visit. Final tooth preparation has been completed for sites Nos. 6 and 11 with open-tray impressions to be taken for final impressions. The healed ovate pontic sites are ideal in three dimensions. **Fig 12.** Astra TiDesign 4.5/5.0 20° stock abutments are in place for Nos. 8 and 9, and 3.5/4.0 non-angulated abutment is in place for No. 12. The abutments have been modified to keep all margins 0.5-mm to 1-mm subgingival. **Fig 13.** Healthy soft tissues are noted in the subgingival transitional zones after removal of the healing abutments. **Fig 14.** Try-in of the final titanium abutments. **Fig 15.** Try-in of the zirconia overcases, which were then sent to the lab for porcelain addition. **Fig 16.** Try-in of the zirconia overcases. Note the room for porcelain and the ideal ovate pontic development from the buccal aspect.

healed. Using local anesthesia, refinements were made to the preparations of teeth Nos. 6 and 11. Open-tray impression copings were placed on all three implants and an impression was taken using the open-tray technique with Precision vinylpolysiloxane impression material (Discus Dental, www.discusdental.com) (Figure 11). A new counter model was obtained along with a bite registration in the maximum intercuspation position (MIP). Tissue heights around each implant were recorded. Lastly, a face-bow transfer was taken to accurately mount all models in their correct relationship. The healing abutments were replaced, and the patient's provisional was relined with SNAP™ (Parkell, www.parkell.com) to fit the refined tooth preparations and recemented with Durelon.

The laboratory prescription called for stock abutments to be modified to keep all margins 0.5-mm to 1-mm subgingival. After pouring and mounting the models, the laboratory technician chose TiDesign™ 4.5/5.0 20° abutments (Astra Tech) for Nos. 8 and 9 to correct the implant angulation and ensure good screw access position. A TiDesign 3.5/4.0 non-angulated abutment (Astra Tech) was chosen for implant No. 12 (Figure 12 through Figure 14). Zirconia framework for the fixed partial denture (FPD) was accomplished using Ekton CAD/CAM technology (Straumann, www.straumann.us). Single zirconia crown copings for teeth Nos. 6, 11, and 12 were similarly fabricated (Figure 15 and Figure 16). After a 2-week period, the abutments, framework, and crown copings were tried in. The case was evaluated clinically as well as with bitewing (BW) and PA digital x-rays. The case fit accurately and needed only minor adjustments (Figure 17). It was returned to the lab for the addition of porcelain, which was accomplished using Noritake CZR (Noritake, www.noritake.co.jp), shade 3M3 cervical, blending to 2M1 incisal. At the following try-in visit the case was placed and contacts and occlusion were checked and adjusted where necessary. Establishment of canine guidance was verified. The patient approved all contours, however additional porcelain was suggested and added to the gingival aspect of the ovate pontic No. 10, as well as on the mesial contact of crown No. 12. Furthermore, a reduction of the glaze was necessary to match the patient's natural dentition.

Once these minor adjustments were completed, the case was ready for insertion. The provisional and all healing abutments were removed and all implants and crown abutments were cleansed with Consepis® (Ultradent Products, www.ultradent.com). Crown Nos. 6 and 11 were inserted with OptiBond Prime and Maxcem Elite™ resin cement (Kerr Corporation). Abutments Nos. 8 and 9 were inserted and torqued to 25 Ncm, as recommended by the manufacturer. Abutment No. 12 was then inserted and torqued to 20 Ncm. All implant restorations were inserted with Premier Implant Cement (Premier Dental, www.premusa.com). The patient returned to the periodontist's office where final digital PA x-rays and digital pictures were taken and occlusion was checked (Figure 18 through Figure 20).

PERIODONTAL MAINTENANCE PHASE

The patient has been very compliant on an alternating 3-month frequency between the restorative dentist and the periodontist office. Considerations to replace his missing lower right teeth have been discussed and will be addressed in the future. Recent 2-year digital PAs and pictures were taken confirming continued periodontal health and radiographic bone maintenance using the platform-switched concept (Figure 21 through Figure 23).

CONCLUSION

The comprehensive treatment of implant cases using the “team” approach concept works to the patient’s benefit. As the medical model has shown, each member’s knowledge of his or her respective area contributes to the overall success of the case.¹⁸

The present case report showed that careful surgical and restorative interdisciplinary planning, along with the inclusion of the laboratory technician in decision-making and excellent motivation of the patient, resulted in a highly functional and esthetic case as well as a satisfied patient. This was reflected in the patient’s posttreatment testimonial: “I really appreciated the seamless experience between offices, and the teamwork and professionalism of both staffs. I am extremely happy with my result.”

ABOUT THE AUTHORS

Robert A. Levine, DDS

Diplomate of American Board of Periodontology; Clinical Professor in Post-Graduate Periodontology and Implantology, Kornberg School of Dentistry, Temple University, Philadelphia, Pennsylvania; Private Practice at The Pennsylvania Center for Dental Implants and Periodontics, Philadelphia, Pennsylvania

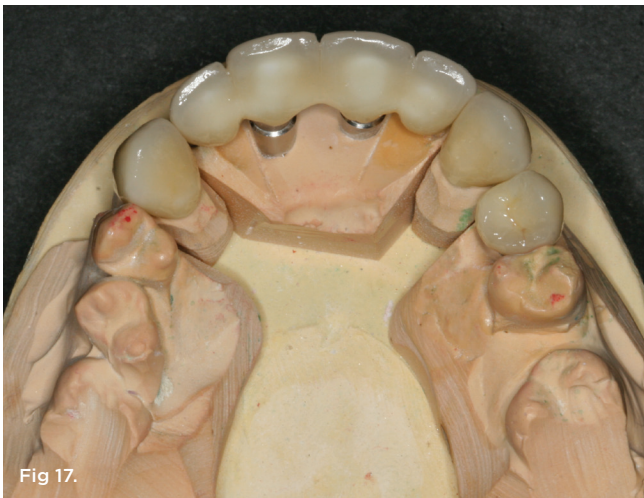

Fig 17.

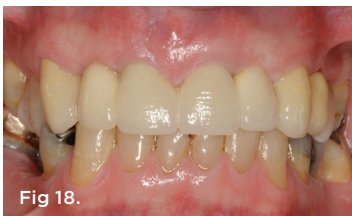

Fig 18.

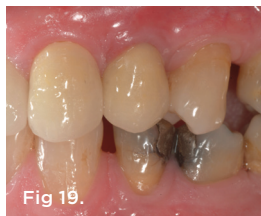

Fig 19.

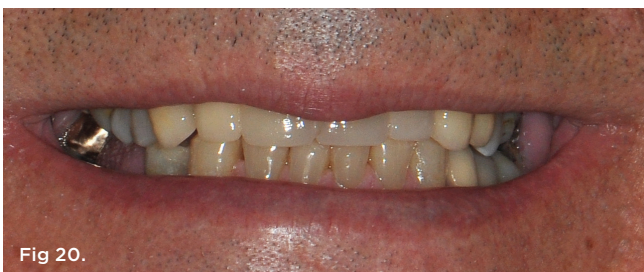

Fig 20.

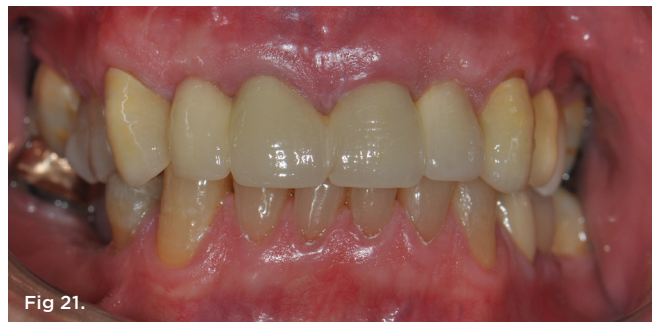

Fig 21.

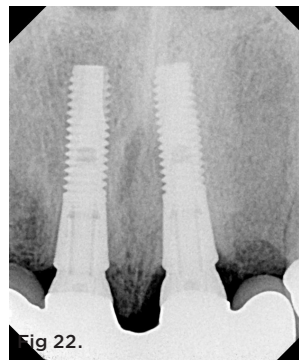


Fig 22.

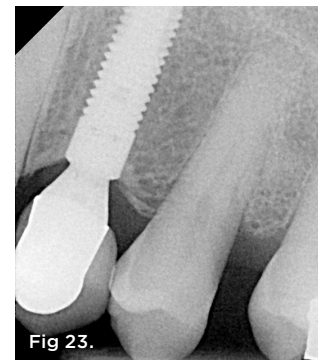

Fig 23.

Fig 17. Final case after porcelain has been baked onto the zirconia on the lab model. Individual crowns were made for Nos. 6, 11, and 12 and a splinted implant bridge for Nos. 7 through 10. **Fig 18.** Final case after insertion. Note excellent soft-tissue response. **Fig 19.** Final case with Nos. 11 and 12 inserted. Note excellent soft-tissue healing. The anatomically ideal soft-tissue scallop of No. 12 reflected the use of the anatomically correct surgical guide, which required bone scalloping (buccal and palatal) prior to implant placement. **Fig 20.** Final smile. **Fig 21.** 2-year post-insertion. Note that the soft-tissue contours are maintaining with slight gingival recession of 1.5 mm noted buccal to No. 11. **Fig 22.** 2-year post-insertion, Nos. 8 and 9. Excellent bone maintenance is evident radiographically. **Fig 23.** 2-year post-insertion, No. 12. Excellent bone maintenance is evident radiographically.

Case Report 1

Guest Back, DDS

Private Practice in Advanced Restorative and Cosmetic Dentistry, Holland, Pennsylvania

REFERENCES

1. Cordaro L. Implants for restoration of single tooth spaces in areas of high esthetic risk. In: Dawson A, Chen S, Buser D et al, eds. *The SAC Classification in Implant Dentistry*. Quintessence Publishing; 2009:50-56.
2. Present S, Levine RA. Single maxillary anterior tooth restoration: Case to replace a non-restorable maxillary left canine illustrates a team approach. *Inside Dentistry* 2010;6(1):58-66.
3. Lorenzana ER. Soft-tissue risk assessment in esthetic restorative and implant dentistry: smile analysis, gingival esthetics, and dental implant report. *Functional Esthetics & Restorative Dentistry*. 2008;2(3):8-18.
4. Buser D, Martin W, Belser UC. Optimizing esthetics for implant restorations in the anterior maxilla: anatomic and surgical considerations. *Int J Oral Maxillofac Implants*. 2004;19(suppl):43-61.
5. Martin WC, Morton D, Buser D. Pre-operative analysis and prosthetic treatment planning in esthetic implant dentistry. In: Buser D, Belser U, Wismeijer D, eds. *ITI Treatment Guide, I: Implant Therapy in the Esthetic Zone: Single Tooth Replacements*. Quintessence Publishing; 2007:9-24.
6. Kois JC. Predictable single tooth peri-implant esthetics: five diagnostic keys. *Compend Contin Educ Dent*. 2004;25(11):895-900.
7. Thomas J. Piezoelectric ultrasonic bone surgery: Benefits for the interdisciplinary team and patients. *Functional Esthetics & Restorative Dentistry*. 2008;2(3):20-24.
8. Levine RA. Soft tissue considerations for optimizing implant esthetics. *Functional Esthetics & Restorative Dentistry*. 2007;1(2):54-62.
9. Salvi GE, Lang NP. Diagnostic parameters for monitoring peri-implant conditions. *Int J Oral Maxillofac Implants*. 2004;19(suppl):116-127.
10. Wilson TG Jr. The positive relationship between excess cement and peri-implant disease: a prospective clinical endoscopic study. *J Periodontol*. 2009;80(9):1388-1392.
11. Levine RA. Guest editorial. *Functional Esthetics & Restorative Dentistry*. 2008;2(3):2.
12. Spear FM. The use of implants and ovate pontics in the esthetic zone. *Functional Esthetics & Restorative Dentistry*. 2007;1(2):64-69.
13. Chen ST, Dahlin C. Connective tissue grafting for primary closure of extraction sockets treated with an osteopromotive membrane technique: surgical technique and clinical results. *Int J Periodontics Restorative Dent*. 1996;16(4):348-355.
14. Landsberg CJ. Socket seal surgery combined with immediate implant placement: a novel approach for single-tooth replacement. *Int J Periodontics Restorative Dent*. 1997;17(2):140-149.
15. Buser D, Halbritter S, Hart C, et al. Early implant placement with simultaneous guided bone regeneration following single-tooth extraction in the esthetic zone: 12-month results of a prospective study with 20 consecutive patients. *J Periodontol*. 2009;80(1):152-162.
16. Norton MR. Multiple single-tooth implant restorations in the posterior jaws: maintenance of marginal bone levels with reference to the implant-abutment microgap. *Int J Oral Maxillofac Implants*. 2006;21(5):777-784.
17. Wagenberg B, Froum SJ. Prospective study of 94 platform-switched implants from 1992 to 2006. *Int J Periodontics Restorative Dent*. 2010;30(1):9-17.
18. Rossein KD. Teaming up for successful implant dentistry. *Functional Esthetics & Restorative Dentistry*. 2007;1(2):12-14.

30 seconds or less could save you 30% or more off your lab bill.

Top quality dental labs are waiting to compete for your business.

Just one click at DoctorDentalLine.com and the best deal is yours!



*Individual savings may vary. Pricing based upon national average.